



## Pituitary Stem Interruption Syndrome (SITP) Diagnosed In Childhood in a Case at the Center Hospitalier Universitaire De Libreville (CHUL)

Nesta Patricia ZIZA NGAILA<sup>1</sup>, Jocelyne DANHO<sup>2</sup>, Daniela NSAME<sup>1</sup>, Natacha BOUMAS<sup>3</sup>, Gladys ANGUEZOMO<sup>1</sup>, Pegguy BILOGHE<sup>1</sup>

<sup>1</sup> Centre Hospitalier Universitaire de Libreville, Gabon

<sup>2</sup> Service d'Endocrinologie, Hopital Militaire d'Abidjan, Côte-d'Ivoire

<sup>3</sup> Centre Hospitalier Universitaire Mère Enfant Fondation Jeanne Ebori, Libreville, Gabon

### ABSTRACT

Published Online: December 08, 2022

Interrupted pituitary stalk syndrome (PITS) is a hypothalamic-pituitary morphological abnormality characterized by a slender or absent pituitary stalk, anterior pituitary hypoplasia, and ectopic posterior pituitary. Hormonal assessment and imaging are crucial for the diagnosis, early management can improve the child's stature prognosis.

We report the case of an 8-year-old child seen in endocrinology consultation for growth retardation. His medical history revealed acute fetal distress at birth, neonatal jaundice and numerous consultations in early childhood for this anomaly. The clinical examination found a statural delay of -3DS, bilateral cryptorchidism, with small testicles. The hormonal balance found multiple pituitary deficits and Magnetic Resonance Imaging showed an absence of the pituitary stalk, anterior pituitary hypoplasia and ectopia of the posterior pituitary. Deficient hormone supplementation was instituted. This case relates the typical picture of hypopituitarism by absence of the pituitary stalk in a context where the disease is probably underdiagnosed due to lack of technical support in sub-Saharan Africa and little known. This explains the diagnostic error in our case, moreover it allows us to pay particular attention to the meticulous monitoring of the growth of children who have presented perinatal anomalies, and the multidisciplinary exploration in the event of growth disorders.

### KEYWORDS:

Growth retardation; congenital hypogonadotropic hypogonadism; pituitary stalk interruption syndrome.

### INTRODUCTION

Stunting in children has multiple causes. The majority occur during pregnancy, probably underestimated in sub-Saharan Africa given the difficulties of technical platforms, it corresponds to the demonstration on Magnetic Resonance Imaging (MRI) of a slender or absent pituitary stalk, anterior pituitary hypoplasia and ectopic posterior pituitary and represents a rare cause of congenital pituitary deficiency (Fujisawa et al., 1987). It is generally discovered in the neonatal period or during childhood. The pituitary deficit is classically revealed by a delay in growth which will lead the practitioner to look for the often varied etiologies, and whose

origins could go back to the perinatal period. In sub-Saharan Africa, financial difficulties as well as the lack of technical facilities make this etiological research laborious, hence the low number of cases published on this subject. We report the case of a child with growth retardation secondary to a syndrome Interruption of the Pituitary Stem.

### OBSERVATION

Old male child referred for endocrinology consultation for growth retardation. He is educated in class of CE2, eldest of a sibling of 4 children, living with his two parents, without notion of similar case in the family. The questioning found acute fetal distress with a sero-blood lump at birth, neonatal jaundice, it was a child who had been consulted several times for growth retardation for whom a nutritional assessment and management had been realized in front of this anomaly without success. There is also hypothyroidism diagnosed 1 year earlier. The examination found a statural delay with a

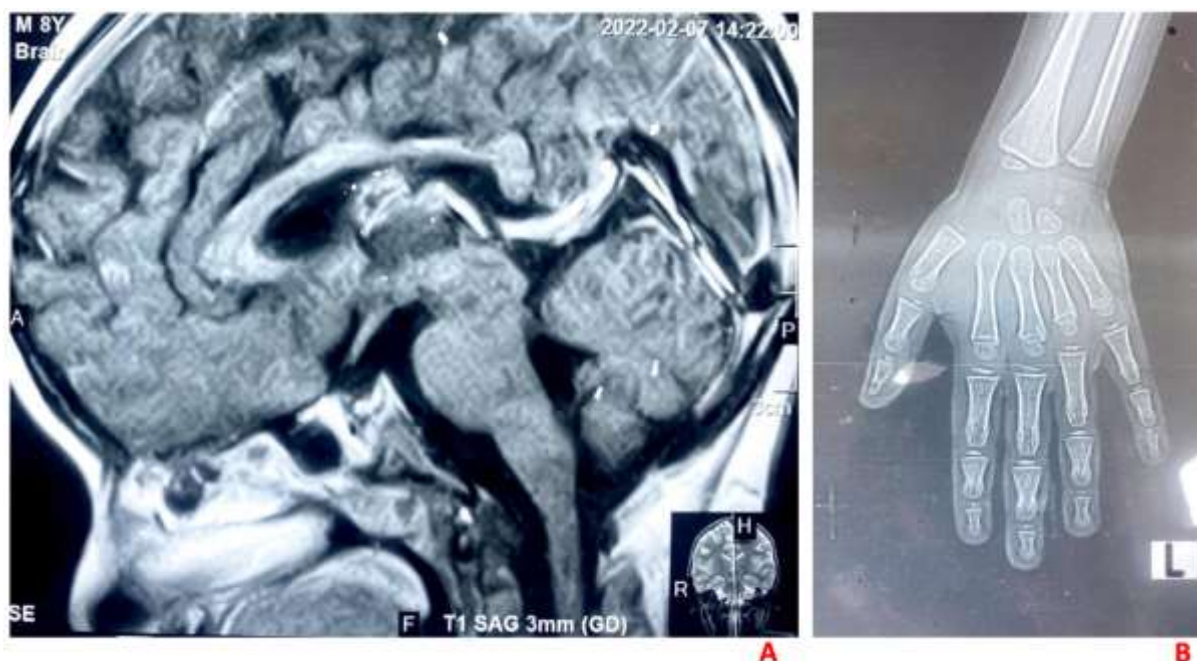
Corresponding Author: Nesta Patricia ZIZA NGAILA

\*Cite this Article: Nesta Patricia ZIZA NGAILA, Jocelyne DANHO, Daniela NSAME, Natacha BOUMAS, Gladys ANGUEZOMO, Pegguy BILOGHE (2022). Pituitary Stem Interruption Syndrome (SITP) diagnosed in childhood in a case at the Center Hospitalier Universitaire de Libreville (CHUL). International Journal of Clinical Science and Medical Research, 2(12), 97-100

## Nesta Patricia ZIZA NGAILA et al, Pituitary Stem Interruption Syndrome (SITP) diagnosed in childhood in a case at the Center Hospitalier Universitaire de Libreville (CHUL)

height of 100 cm (- 3 SD), a normal weight curve, a micropenis, bilateral cryptorchidism with small testicles. Examination of other devices was unremarkable. Hormonal assessment revealed low cortisol levels at 30 µg/mL, central hypothyroidism (TSH: 1.65 µU/ml FT4: 4 pmol /L), normal basal growth hormone (1.0 mIU /L), FSH low (0.3 IU/L) normal prolactin (21.4 ug/L). Pelvic ultrasound showed bilateral testicular ectopia superficial on the right and prescrotal on the left with small, hypochoic testicles.

Pituitary MRI in sagittal and coronal sections (Figure 1A) revealed a syndrome of interruption of the pituitary stalk with ectopic posterior pituitary and hypoplastic anterior pituitary stuck to the bottom of the sella turcica. The X-ray of the hand gave a bone age of 03 years (Figure 1B). The patient was substituted with Hydrocortisone cp 20 mg/day, L -thyroxine 12.5 mg/day, Somatropin 1mg/day and is monitored regularly. Monitoring will be clinical and biological with monitoring of growth and hormones.



**Figure 1: Pituitary MRI in sagittal and coronal sections (A) and x-ray of the hand gives a bone age of 3 years (B)**

### DISCUSSION

Interrupted pituitary stalk syndrome (SITP) is a hypothalamic-pituitary morphological abnormality first described by Fujisawa in 1987 (Fujisawa et al., 1987). Very rare pathology with an estimated incidence of 1 in 200,000 births, this syndrome is usually diagnosed in the neonatal period or in early childhood in a clinical picture of anterior pituitary insufficiency of variable clinical expression (Bar et al., 2015). This congenital developmental anomaly of the pituitary gland is a diagnostic emergency, the endocrine deficit becoming more and more intense and multiple, the rapidity of the introduction of hormone replacement therapy determines the prognosis (Boueilh et al., 2017). Marmouch et al in Tunisia reported a case of SITP (Marmouch et al., 2016), however, in Sub-Saharan Africa few data exist on this disease hence the interest of this case written in Gabon where the diagnostic error in a context of insufficient technical facilities, stigmatization of patients, barriers to care, means that the diagnosis of these rare pathologies is often delayed. The median age at diagnosis found by Céline bar et al in France was about 4 years (Bar et al., 2015), while our diagnosis was made at the age of 7 years. Similarly, some publications have reported a post-pubertal age at diagnosis (Marmouch et al., 2016; Riancho et al., 2020).

According to the literature, this pathology mainly affects boys. (Bar et al., 2015) as in our case. With regard to etiological research, etiopathogenic hypotheses have been proposed for SITP by Fujisawa (Fujisawa et al., 1987), among these, perinatal suffering could be suggested in our patient, given his neonatal history. Perinatal suffering can be traumatic (fetal suffering, anoxia, breech birth), either purely mechanical by stretching or section of the pituitary stalk by the sellar diaphragm, or vascular by anoxia, ischemia or hemorrhage. But the birth conditions are probably a consequence rather than a cause of SITP (Boueilh et al., 2017; Fujisawa et al., 1987; Marmouch et al., 2016; Riancho et al., 2020).

In addition, A genetic antenatal origin could be implicated, by mutation of the genes coding for the transcription factors in the anterior pituitary ontogeny (Miyamoto et al., 2001). The bilateral micropenis and cryptorchidism found in this patient are identified as forms probably with antenatal onset. Our patient had multiple deficits affecting in particular the corticotrophic, gonadotropic and thyrotrophic axes, while pituitary deficits that can be isolated are classically described in SITP; but in most cases it is a combined GH deficiency (Castets et al., 2022) in our case the normal dosage of growth hormone.

## **Nesta Patricia ZIZA NGAILA et al, Pituitary Stem Interruption Syndrome (SITP) diagnosed in childhood in a case at the Center Hospitalier Universitaire de Libreville (CHUL)**

The absence of diabetes insipidus, initial and after supplementation of the hypophyseal axes, especially corticotropic, testifies to the functional nature of the posterior pituitary, confirmed on the MRI by the hypersignal. Indeed, most studies have shown a good correlation between the presence of the hypersignal and the functional character of the posterior pituitary. (Chen et al., 1999).

The delay in diagnosis in our context, apart from the rarity and ignorance of this pathology, can also be linked to the cost of the hormonal assessment which is not currently covered by the National Health Insurance and Social Guarantee Fund, but which must be sent for analysis to international laboratories. Added to this is the cost of imaging, which in our case allowed us to better support our diagnosis.

The patient received hormone replacement therapy, the ultimate goal being to allow growth in stature and make up for hormonal deficits.

Orchidopexy as well as the age of onset of gonadotropin supplementation has been discussed. Indeed, in boys with Congenital Hypogonadotropic Hypogonadism diagnosed in the neonatal period, treatment with androgens or recombinant gonadotropins is now proposed during this period to allow penile growth and promote testicular descent; only this treatment allows an increase in testicular volume and could facilitate the subsequent management of fertility. When the diagnosis is late, in children before adolescence, pubertal induction is indicated around 12-13 years of age (Castets et al., 2022).

Concerning surgery, an early orchidopexy would reduce the thermal dysregulation at the origin of disorders of the maturation of the testicle, would allow an improvement of the testicular development with reduction of the risk of cancerization (Parmentier et al., 2013)

### **CONCLUSION**

The syndrome of interruption of the pituitary stalk, of recent knowledge, is not negligible; it is important to look for it in the aftermath of a head trauma or fetal distress. The risk is the progressive evolution towards a pan hypopituitarism, which it is necessary to seek regularly.

**FUNDING:** This work has not received any specific subsidy from the public, commercial or non-profit funding organizations.

### **AUTHORS' CONTRIBUTIONS**

NPZNG is the main author, designed the study and developed the protocols. JD collected and analyzed the data. DN participated in the development of protocols. NB wrote and corrected the manuscript. GA reviewed and made the necessary editorial corrections to the manuscript. PB supervised this work and definitively approved the submission of the revised version. All authors have read and approved the final version.

### **ETHICS APPROVAL AND CONSENT TO PARTICIPATE**

The study protocol was carried out in accordance with the Helsinki declaration. No name or clue that could reveal the identity of the patient has been written on the pre-established technical sheet to guarantee confidentiality and all records have been kept in a safe place.

**ACKNOWLEDGEMENTS:** We would like to thank the **Service Edition Publication** for correcting this document.

**CONFLICTS OF INTEREST:** The authors have no conflicts of interest to declare.

### **REFERENCES**

1. Bar, C., Zadro, C., Diene, G., Oliver, I., Pienkowski, C., Jouret, B., Cartault, A., Ajaltouni, Z., Salles, J.-P., Sevely, A., 2015. Pituitary stalk interruption syndrome from infancy to adulthood: clinical, hormonal, and radiological assessment according to the initial presentation. *PLoS One* 10, e0142354.
2. Boueilh, T., Bassi, C., Rouleau, S., le Crugel, S., Moal, V., de Casson, F.B., Coutant, R., Mirebeau-Prunier, D., Reynier, P., Homedan, C., 2017. Le syndrome d'interruption de la tige pituitaire: une cause rare et sévère d'insuffisance hypophysaire À propos du diagnostic biologique d'un cas de découverte néonatale, in: *Annales de Biologie Clinique*. pp. 215–221.
3. Castets, S., Thomas-Teinturier, C., Villanueva, C., Saveanu, A., Coutant, R., Léger, J., Reynaud, R., 2022. Diagnostic et prise en charge du déficit hypophysaire congénital en pédiatrie. *Perfectionnement en Pédiatrie*.
4. Chen, S., Léger, J., Garel, C., Hassan, M., Czernichow, P., 1999. Growth hormone deficiency with ectopic neurohypophysis: anatomical variations and relationship between the visibility of the pituitary stalk asserted by magnetic resonance imaging and anterior pituitary function. *J Clin Endocrinol Metab* 84, 2408–2413.
5. Fujisawa, I., Kikuchi, K., Nishimura, K., Togashi, K., Itoh, K., Noma, S., Minami, S., Sagoh, T., Hiraoka, T., Momoi, T., 1987. Transection of the pituitary stalk: development of an ectopic posterior lobe assessed with MR imaging. *Radiology* 165, 487–489.
6. Marmouch, H., Graja, S., Arfa, S., Boubaker, F., Khochtali, I., 2016. Syndrome d'interruption de la tige pituitaire à révélation tardive. *Pan African Medical Journal* 23.
7. Miyamoto, J., HASEGAWA, Y., Ohnami, N., Onigata, K., Kinoshita, E., Nishi, Y., Tachibana, K.,

**Nesta Patricia ZIZA NGAILA et al, Pituitary Stem Interruption Syndrome (SITP) diagnosed in childhood in a case at the Center Hospitalier Universitaire de Libreville (CHUL)**

- Hasegawa, T., 2001. Development of growth hormone and adrenocorticotrophic hormone deficiencies in patients with prenatal or perinatal-onset hypothalamic hypopituitarism having invisible or thin pituitary stalk on magnetic resonance imaging. *Endocr J* 48, 355–362.
8. Parmentier, B., Peycelon, M., Maurin, S., Meyer, F., Audry, G., 2013. Chirurgie de l'ectopie testiculaire: de plus en plus tôt? *Revue générale de Chirurgie* 33–36.
  9. Riancho, J., Maione, L., Khalfi, K., Verdalle-Cazes, M., Scharbarg, E., Viry, C., Lefebvre, H., 2020. Syndrome d'interruption de la tige pituitaire à révélation tardive à l'âge adulte. À propos d'un cas, in: *Annales d'Endocrinologie*. Elsevier, pp. 297–298.